
This is an electronic reprint of the original article.
This reprint may differ from the original in pagination and typographic detail.

Lewis, John D.; Acosta, Henriette; Tuulari, Jetro J.; Fonov, Vladimir S.; Collins, D. Louis; Scheinin, Noora M.; Lehtola, Satu J.; Rosberg, Aylin; Lidauer, Kristian; Ukharova, Elena; Saunavaara, Jani; Parkkola, Riitta; Lähdesmäki, Tuire; Karlsson, Linnea; Karlsson, Hasse
Allometry in the corpus callosum in neonates: Sexual dimorphism

Published in:
Human Brain Mapping

DOI:
[10.1002/hbm.25977](https://doi.org/10.1002/hbm.25977)

Published: 15/10/2022

Document Version
Publisher's PDF, also known as Version of record

Published under the following license:
CC BY-NC









Please cite the original version:
Lewis, J. D., Acosta, H., Tuulari, J. J., Fonov, V. S., Collins, D. L., Scheinin, N. M., Lehtola, S. J., Rosberg, A., Lidauer, K., Ukharova, E., Saunavaara, J., Parkkola, R., Lähdesmäki, T., Karlsson, L., & Karlsson, H. (2022). Allometry in the corpus callosum in neonates: Sexual dimorphism. *Human Brain Mapping*, 43(15), 4609-4619. <https://doi.org/10.1002/hbm.25977>

This material is protected by copyright and other intellectual property rights, and duplication or sale of all or part of any of the repository collections is not permitted, except that material may be duplicated by you for your research use or educational purposes in electronic or print form. You must obtain permission for any other use. Electronic or print copies may not be offered, whether for sale or otherwise to anyone who is not an authorised user.

RESEARCH ARTICLE

WILEY

Allometry in the corpus callosum in neonates: Sexual dimorphism

John D. Lewis¹  | Henriette Acosta^{2,3}  | Jetro J. Tuulari^{3,4,5,6}  |
 Vladimir S. Fonov¹  | D. Louis Collins¹  | Noora M. Scheinin^{3,6} |
 Satu J. Lehtola³ | Aylin Rosberg^{3,7} | Kristian Lidauer³  | Elena Ukharova^{3,8} |
 Jani Saunavaara^{3,9} | Riitta Parkkola^{3,7} | Tuire Lähdesmäki^{3,10} |
 Linnea Karlsson^{3,6,11,12}  | Hasse Karlsson^{3,6} 

¹Montreal Neurological Institute and Hospital, McGill University, Quebec, Canada

²Department of Psychiatry and Psychotherapy, Philipps University of Marburg, Marburg, Germany

³FinnBrain Birth Cohort Study, Turku Brain and Mind Center, Institute of Clinical Medicine, University of Turku, Turku, Finland

⁴Turku Collegium for Science and Medicine and Technology, University of Turku, Turku, Finland

⁵Department of Future Technologies, University of Turku, Turku, Finland

⁶Department of Psychiatry, University of Turku and Turku University Hospital, Turku, Finland

⁷Department of Radiology, University of Turku and Turku University Hospital, Turku, Finland

⁸Department of Neuroscience and Biomedical Engineering, Aalto University School of Science, Espoo, Finland

⁹Department of Medical Physics, Turku University Hospital, Turku, Finland

¹⁰Department of Pediatric Neurology, University of Turku and Turku University Hospital, Turku, Finland

¹¹Centre for Population Health Research, University of Turku and Turku University Hospital, Turku, Finland

¹²Department of Pediatrics and Adolescent Medicine, Turku University Hospital and University of Turku, Turku, Finland

Correspondence

John D. Lewis, Montreal Neurological Institute and Hospital, McGill University, Montreal, Quebec, Canada.

Email: jlewis@bic.mni.mcgill.ca

Funding information

Academy of Finland, Grant/Award Numbers: 134950, 1350941, 253270, 253346, 264363, 308176; Hospital District of Southwest Finland State Research Grant, Grant/Award Numbers: K3562, P3003, P3006, P3498, P3654; NARSAD Brain and Behavior Research Foundation, Grant/Award Number: 1956; Yrjö Jahnssonin Säätiö, Grant/Award Number: 6847

Abstract

The corpus callosum (CC) is the largest fiber tract in the human brain, allowing inter-hemispheric communication by connecting homologous areas of the two cerebral hemispheres. In adults, CC size shows a robust allometric relationship with brain size, with larger brains having larger callosa, but smaller brains having larger callosa relative to brain size. Such an allometric relationship has been shown in both males and females, with no significant difference between the sexes. But there is some evidence that there are alterations in these allometric relationships during development. However, it is currently not known whether there is sexual dimorphism in these allometric relationships from birth, or if it only develops later. We study this in neonate data. Our results indicate that there are already sex differences in these allometric relationships in neonates: male neonates show the adult-like allometric relationship between CC size and brain size; however female neonates show a significantly more positive allometry between CC size and brain size than either male neonates or female adults.

John D. Lewis and Henriette Acosta contributed equally to this work.

This is an open access article under the terms of the [Creative Commons Attribution-NonCommercial](https://creativecommons.org/licenses/by-nc/4.0/) License, which permits use, distribution and reproduction in any medium, provided the original work is properly cited and is not used for commercial purposes.

© 2022 The Authors. *Human Brain Mapping* published by Wiley Periodicals LLC.

The underlying cause of this sexual dimorphism is unclear; but the existence of this sexual dimorphism in neonates suggests that sex-differences in lateralization have prenatal origins.

KEYWORDS

brain size, interhemispheric connectivity, lateralization, sex

1 | INTRODUCTION

The corpus callosum (CC) is the largest fiber bundle in the human brain, interconnecting the two hemispheres. It is estimated to consist of more than 200 million fibers. These fibers interconnect homologous regions in the two hemispheres, and play an important role in almost all aspects of cognition, from vision to language (Akelaitis, 1941; Hines et al., 1992; Iwamura, 2000; Mitchell & Blakemore, 1970; Selnes, 1974; Westheimer & Mitchell, 1969). It has been a focus of research for decades, but with some considerable inconsistencies in results.

One key locus of these inconsistencies has been sexual dimorphism. Several reports of sexual dimorphism of the CC have been published (Clarke et al., 1989; DeLacoste-Utamsing & Holloway, 1982; Witelson, 1989), but with small sample sizes, and numerous methodological problems, including inaccuracies introduced by a nonplanar midline; distortions due to variability in where the fornix appears to join the CC; and the presence of blood vessels. Perhaps the most severe of these methodological problems was noted by Bishop and Wahlsten (1997), who pointed out that the CC, like most every other substructure of most every other organism, should be expected to scale allometrically with brain size (Huxley & Teissier, 1936), and this appears to be the case, at least for primates (Ardesch et al., 2021). Analyses have often used a linear regression, and have controlled for brain size; or have used a ratio of CC size to brain size. In either case, the linear assumption is problematic (Packard & Boardman, 1988; Smith, 2005). Allometric scaling does not assume linearity; allometric scaling assumes that the relation of Y to X is captured by the exponential function $Y = aX^b$. Thus, Y is not linearly related to X , unless $b = 1$; rather $\log(Y)$ is linearly related to $\log(X)$. If $b = 1$, Y increases proportionally with X ; if $b < 1$, Y increases less than proportionally with X ; if $b > 1$, Y increases greater than proportionally with X . For a measure of area, such as the CC, proportional growth would have Y increasing to the two-thirds power of the volume of X , as per the geometric rule relating, for example, the cross-sectional area of a sphere to its volume.

Since men and women generally differ in brain size, not taking this allometric relationship into account can produce ostensible differences in the size of its substructures, including the CC; differences which are, in fact, not differences if the allometric relationship is taken into account. Bishop and Wahlsten (1997) produced a meta-analysis of existing literature, taking this allometric relationship into account, and concluded that there was no evidence of sexual dimorphism in the CC. Subsequent studies of the CC that accounted for the allometric relation between the CC area and forebrain volume (FBV) supported the notion that men and women show a relationship between

CC size and brain size that is not sexually dimorphic (Bruner et al., 2012; Jäncke et al., 1997; Jäncke et al., 2019; Jäncke & Steinmetz, 1998, 2003; Leonard et al., 2008; Luders et al., 2014).

Though the existing evidence does not support the idea of sexual dimorphism in the CC in typical adults, there is some evidence that this may not hold for development (Schmied et al., 2020). Schmied et al. (2020) reported that there was no sexual dimorphism in infants at 6 months of age, but that males and females showed divergent trajectories thereafter, with males showing more rapid expansion of the CC. This result does suggest that there is transient sexual dimorphism in these allometric relationships after 6 months or age (the earliest time-point in their longitudinal sample); but it does not suggest that there is not sexual dimorphism before 6 months of age. To get a clearer picture of the developmental trajectory of these allometric relationships the current study addresses this question in neonates. We measure the CC and FBV in male and female neonates, and compute the allometric relationship in either sex. We ask whether or not those relationships differ for male and female neonates, and how they compare to the same relationships in adults.

2 | MATERIALS AND METHODS

2.1 | Participants

Participants were neonates whose parents were recruited as part of the FinnBrain Birth Cohort Study (www.finnbrain.fi) (Karlsson et al., 2018). Written informed consent was obtained from all parents. The study was conducted according to the Declaration of Helsinki and was reviewed and approved by the Ethics Committee of the Hospital District of Southwest Finland. Neuroimaging data were collected from 189 neonates at the age of 1–8 weeks after birth. Inclusion criteria for neuroimaging were gestational age at birth ≥ 35 weeks and birth weight > 1500 g. Exclusion criteria were previously diagnosed CNS anomalies or abnormal findings on a previous magnetic resonance imaging (MRI) scan. Of the 189 participants, 64 were excluded due to failed MRI scanning or motion artifacts in the MR images. In the final sample we included these 125 neonates (female: 44%, age after birth [days]: $M = 26.2$, $SD = 7.7$, range = 11–54).

2.2 | MRI acquisition

Participants were scanned with a Siemens Magnetom Verio 3 T scanner (Siemens Medical Solutions, Erlangen, Germany) during natural

sleep. The imaging protocol included a sagittal 3D-T1 MPRAGE (Magnetization Prepared Rapid Acquisition Gradient Echo) sequence (TR: 1900 ms, TE: 3.26 ms, inversion time: 900 ms) with whole brain coverage and isotropic voxels of 1.0 mm³. There was also an axial T2-PD-TSE (Dual-Echo Turbo Spin Echo) sequence (repetition time (TR): 12070 ms, effective echo times (TE): 13 ms and 102 ms), as well as a diffusion sequence. Here, we used only the T1 and T2 data. All brain images were assessed for incidental findings by a pediatric neuroradiologist.

2.3 | Neonate template

All available good quality imaging data were used to create a dual-contrast neonate template. Each subject's T1 and T2 were nonuniformity corrected (Sled et al., 1998), and then their T1, as well as a left-right flipped copy, was linearly registered to the 6-month symmetric template from the Infant Brain Imaging Study—the youngest of the existing templates based in the Talairach-like MNI152 symmetric template, an average of 152 T1-weighted images (Collins et al., 1994; Fonov et al., 2009, 2011). The average scaling from the native MRIs to the template was then computed, and the inverse used to scale the template to the average size of the neonate population; this served as an initial target for construction of the neonate template. An iterative procedure that minimizes the mean squared intensity difference between the current iteration of the template–template;–and each subject's MRI, and minimizes the magnitude of all deformations used to map template; to each subject's MRI was used to construct the template, as described in Fonov et al. (2011). This method was applied to produce linear and nonlinear transformations from the template to each scan, then these transformations were used to map the subject's T1s to the template space, where they were averaged to create the neonate T1 symmetric template. Finally, the intensity of the T1 template was linearly scaled so that it had the same intensity range as the MNI152 T1 symmetric template. The T2 data and a left-right flipped copy of them were then registered to their T1 counterparts, and these transformations were combined with the T1 transformations to map the T2 scans into the template space where they were averaged to create the T2 symmetric template; as with the T1 template, the intensity of the T2 template was linearly scaled so that it had the same intensity range as the MNI152 T2 symmetric template.

2.4 | FBV measurement

The multi-contrast template was then manually labelled in order to derive masks of the structures of interest. To ensure that these labels were accurate, we created multiple copies of the template, each warped differently, to represent the morphological variability in the sample. To achieve this, we clustered the data with Ward's method (Ward, 1963). The morphological variability in the sample was well-represented by 21 clusters. We then warped the multi-contrast template to the subject at the center of each of these clusters. We then labelled each of these variants (without the raters' awareness that

they were, in fact, identical except for being different deformations), and then unwarped the labelled templates, and took the majority label at each voxel. For the case at hand, that is, the forebrain, we used all gray-matter, white-matter, subcortical, ventricular, and upper brain-stem voxels to create a mask for the neonate template. This forebrain mask was then transformed from the neonate template to overlay each subject's MRI using the inverse of the deformations computed above, and used to extract the subject's FBV via *mincstats*.

2.5 | CC measurement

The CC was first defined on the MNI152 template (for another project [Lewis et al., 2013]). The boundary and 25 divisions of the CC were identified on the midsagittal slice of the template. The CC was divided into 25 subregions in order to provide high-resolution results while maintaining comparability with the five regions utilized by Clarke et al. (1989). This division into 25 subregions has been used previously with diffusion tractography to map the regions of the brain connected by different parts of the CC (Lewis et al., 2013); this mapping is used here to assess the allometric relationship in the anterior and the posterior of the brain, separately (see section 2.6). The boundary and divisions of the CC were established using a semiautomated procedure based on Clarke's method (Clarke et al., 1989). The procedure was as follows. The midsagittal slice of the template was extracted and upsampled to 0.1 mm × 0.1 mm. An intensity-based flood-fill was used to establish an initial boundary of the CC. An implementation of the active contour algorithm was then used to transform this initial estimate into a smoothed boundary at the centre of the gradient at the edge of the CC. Lines were then radiated from the geometric centroid of the CC at 1-degree intervals, and for each line that crossed the CC, the point midway between the two points of intersection with the boundary was determined, and the shortest length line that crossed the CC through that point was determined. The curved line that passed through the midpoint of each of these lines and extended to the CC boundary on either end defined the midline. The midline was divided into 25 equal length segments. The shortest length lines that crossed the CC at the points defined by these midline segments defined the subregion boundaries. The subregions are identified as 1–25 from rostral to caudal as illustrated in Figure 1. The method is described in more detail in Lewis et al. (2009) and Lewis et al. (2013).

The MNI152 template was then linearly and nonlinearly registered to the neonate template via a series of intermediaries, that is, the 24, 12, and 6 month templates (Fonov et al., 2011), using ANTs with mutual information (Avants et al., 2009). These intermediary templates were used to minimize the issues related to intensity and morphological changes over development. The resulting transforms were concatenated in order to bring the CC from the MNI152 template to the neonate template. The neonate template was then linearly and nonlinearly registered to each of the neonate subjects in order to overlay the CC on each, and to measure the CC area in each, as depicted in Figure 2.

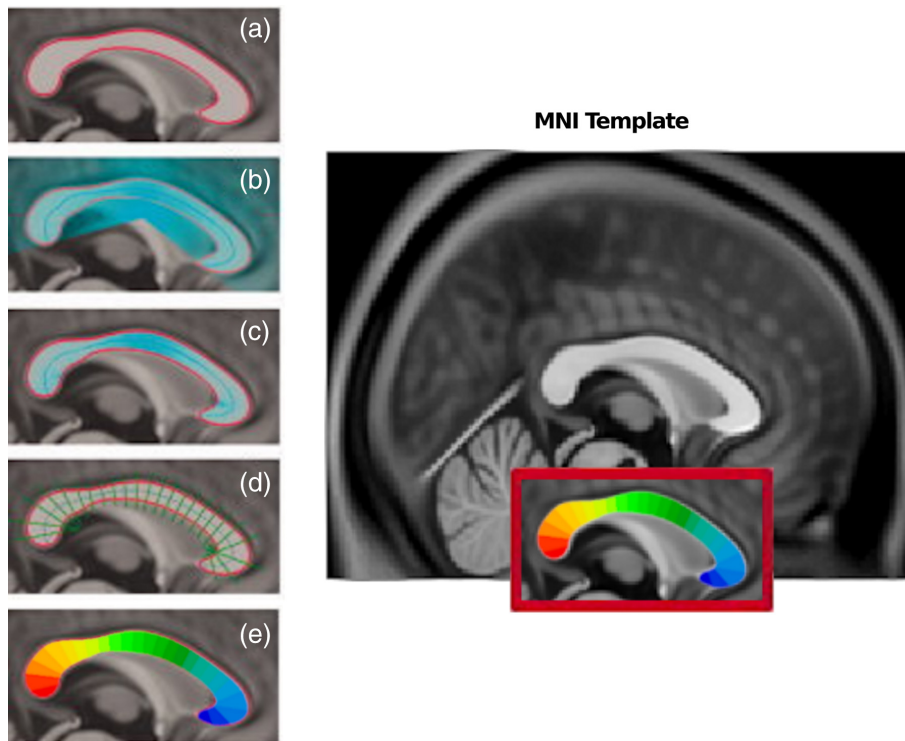


FIGURE 1 The definition of the corpus callosum on the MNI152 template. The boundary of the CC is determined via an active contour (a); (b) lines are radiated from the geometric centroid, and the midpoints of those that intersect the CC are calculated; (c) the shortest lines that cross the CC passing through the midpoints in b are found, and their midpoints are calculated; (d) the curve passing through the midpoints in c and extending to the CC boundary is divided into 25 equal length segments; the shortest lines crossing the CC at the ends of a segment define the subregion boundaries; (e) in color

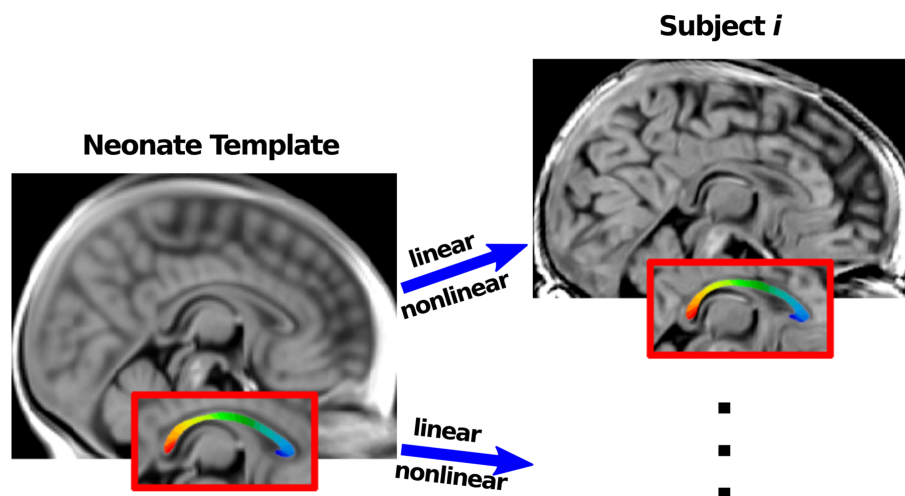


FIGURE 2 A schematic of the method of measuring the corpus callosum in the neonates. The neonate template is linearly and nonlinearly registered to each subject in order to overlay the CC subdivisions on that subject. The cross-sectional area of the CC is then calculated for that individual

2.6 | Analysis

The CC area and FBV measures were then submitted to a regression analysis, in order to determine the value of the exponent in the allometric equation:

$$CC_{area} = constant * FBV^{exponent}, \quad (1)$$

For a 3D substructure showing proportional growth, the exponent of such an equation would be 1. But since for the CC we are measuring the cross-sectional area, in the case of proportional growth, the exponent of this allometric equation would be 2/3 (Schmidt-

Nielsen & Knut, 1984). This equation is transformed into a linear form by taking the log of either side, producing:

$$\log(CC_{area}) = constant + exponent * \log(FBV), \quad (2)$$

allowing its use in a linear regression analysis. The analyses determine the exponents, that is, the slope of the regression lines, which we will then compare between the sexes, and with the slopes of the fit lines for the regressions reported by Jäncke and Steinmetz (1998) for adult data via a similar analysis. All analyses control for age at time of scan (gestational weeks to birth and postnatal days).

TABLE 1 The sample descriptives

Variable	Males $N = 70$ $M \pm SD$ (range)	Females $N = 55$ $M \pm SD$ (range)	Sex difference (p -value)
Age (days)	26.4 \pm 7.9 (11–43)	26.0 \pm 7.4 (14–54)	.788
Gestational weeks	39.9 \pm 1.1 (37.6–42)	39.9 \pm 1.2 (36.3–42.1)	.868
Total CC area (mm ²)	139.62 \pm 18.31 (98.00–187.62)	135.86 \pm 20.03 (91.26–169.77)	.276
Forebrain volume (mm ³)	412,757.74 \pm 29,537.18 (357,502.12–473,818.88)	395,701.92 \pm 27,871.48 (343,834.00–450,826.00)	.001
Anterior CC area (mm ²)	87.57 \pm 12.24 (60.25–116.71)	86.23 \pm 15.29 (56.60–116.49)	.586
Frontal lobe volume (mm ³)	183,362.25 \pm 13,586.89 (158,586.12–212,617.62)	173,347.90 \pm 12,933.20 (146,955.88–199,547.50)	<.001
Posterior CC area (mm ²)	52.05 \pm 9.48 (31.03–80.07)	49.63 \pm 8.31 (33.73–68.34)	.138
Posterior lobes volume (mm ³)	229,395.49 \pm 17,382.20 (198,916.00–265,237.25)	222,354.02 \pm 16,080.81 (191,251.75–255,145.88)	.022

First, we investigated the sex-specific association between FBV and total CC area, that is, the two-way interaction between sex and the log of FBV regressed on the log of total CC area. In subsequent post hoc regression analyses we investigated the association between the log of FBV and the log of total CC area for male and female neonates separately, and compared the results to those of their adult counterparts, as reported by Jäncke and Steinmetz (1998) from a similar analysis. Each of these comparisons used the 95% confidence intervals (CIs) of the β -values corresponding to the slopes estimated by the regression analyses (using the *confint* function in R) to compare between the sexes or with the adult slopes reported by Jäncke and Steinmetz (1998). For the neonate data, we also report the significance of the interaction term for sex. For the comparisons with the results reported by Jäncke and Steinmetz (1998), we computed one-sample t -tests.

Assumptions of the regression analyses were checked by visual inspection of the correct specification of the model (Residuals vs. Fitted plot, Lowess line), the normal distribution of the residuals (Normal Q-Q plot), the homoscedasticity (Scale-Location diagram) and critical outliers (Residuals vs. Leverage plot, Cook's distance) (using the *plot* function in R). Assumptions were met in all analyses. Homoscedasticity was additionally tested by means of the Goldfeld-Quandt-test (using the *gqtest* function in R); a p -value $>.05$ indicates homoscedasticity. Homoscedasticity was met in all analyses.

Lewis et al. (2013) also provide the mapping between cortical regions and the 25 CC segments, based on diffusion tractography. We use this mapping as the basis for two subanalyses of this allometric relation: for the frontal lobe and the anterior CC; and for the posterior lobes and the posterior CC. According to the results of Lewis et al. (2013), the frontal lobe connections via the CC pass through segments 1–16, and segments 17–25 interconnect the parietal, occipital, and temporal lobes. To measure the volumes of the frontal lobes versus posterior lobes, we utilized the divisions of the gray and white matter provided by *lobe_segment* (Collins et al., 1999). Since this software was originally designed to work with the MNI152 t1 template, in

TABLE 2 The results for the assessment of the allometric relation between $\log(\text{totalCC}_{\text{area}})$ and $\log(\text{ForeBrain}_{\text{volume}})$ in male and female neonates. Note that the β of either group falls outside of the CI(95%) of the other

Group	β	SE	CI(95%)
Male neonates	0.65	0.23	0.18, 1.11
Female neonates	1.31	0.25	0.80, 1.82

TABLE 3 The results for the assessment of the allometric relationship between $\log(\text{anteriorCC}_{\text{area}})$ and $\log(\text{FrontalLobe}_{\text{volume}})$ in male and female neonates. Note that the β of either group falls outside of the CI(95%) of the other

Group	β	SE	CI(95%)
Male neonates	0.69	0.24	0.22, 1.16
Female neonates	1.45	0.28	0.9, 2.01

order to use it, we linearly and nonlinearly registered the MNI152 t1 template to the Neonate template, again via a series of intermediaries, as described above, and transformed the *lobe_segment* atlases to overlay the Neonate template.

3 | RESULTS

Table 1 provides the sample descriptives. The results of the regression analyses are shown in Tables 2–4 and Figures 3–5. The male neonates show an allometric relationship with a slope of almost that of proportional growth, that is, the CC scales with brain size with an exponent only slightly different from 2/3. The female neonates show an allometric relationship with a slope that significantly exceeds the slope of proportional growth, and which is also significantly greater than that of the male neonates. With sex as an interaction term, the interaction is significant ($p = .029$); thus the results show sexual dimorphism in

TABLE 4 The results for the assessment of the allometric relationship between $\log(\text{posteriorCC}_{\text{area}})$ and $\log(\text{PosteriorLobes}_{\text{volume}})$ in male and female neonates. Note that the β of either group falls within the $CI(95\%)$ of the other

Group	β	SE	CI(95%)
Male neonates	0.69	0.32	0.05, 1.32
Female neonates	0.94	0.31	0.31, 1.56

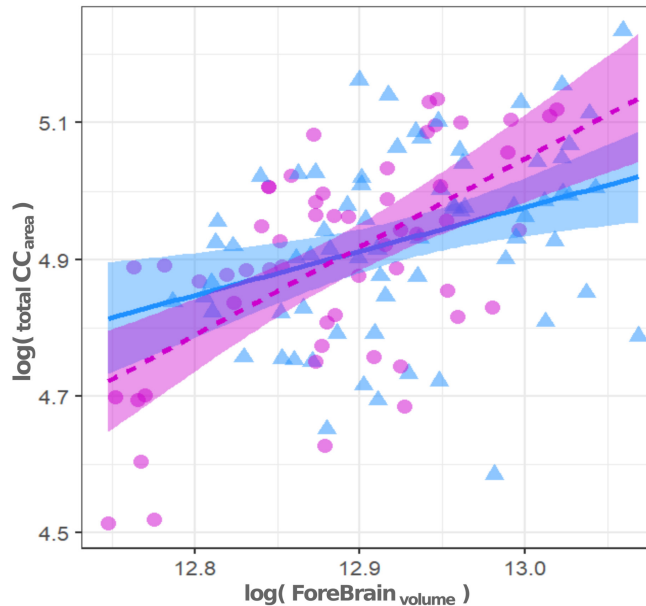


FIGURE 3 A scatter plot of the allometric relation between $\log(\text{totalCC}_{\text{area}})$ and $\log(\text{ForeBrain}_{\text{volume}})$ in male and female neonates. Males are shown as blue triangles; females as magenta circles. The male regression line is solid blue; the female regression line is dashed magenta. The slope of the regression line in male neonates is 0.65; the slope of the regression line in female neonates is 1.31. These slopes are significantly different, that is, sexually dimorphic ($p = .029$). Note that the regression controls for age at scan (in terms of gestational weeks to birth and postnatal days)

the allometric relationship between CC size and brain size in neonates. Further, female neonates show an allometric relationship with a slope that is significantly greater than the slope in the relationship reported by Jäncke and Steinmetz (1998) for their adult counterparts, that is, 1.31 versus 0.66. The male neonates show an allometric relationship with a slope that is greater than that of their adult counterparts, but not significantly so, that is, 0.65 versus 0.52.

Figure 3 shows the scatter-plot of the allometric relationships for the male and female neonates. As can be seen by the nonoverlap of the confidence intervals for each sex with the fit-line for the opposite sex, the allometric relationship between total CC area and FBV is sexually dimorphic ($p = .029$). This conclusion can also be read from Table 2.

Figure 4 (left) shows the scatter-plot of the allometric relationships for the female neonates and their adults counterparts, as

reported by Jäncke and Steinmetz (1998). Figure 4 (right) shows the scatter-plot of the allometric relationships for the male neonates and their adults counterparts, as reported by Jäncke and Steinmetz (1998). As can be seen by the nonoverlap of the confidence intervals for the female neonates with the fit-line for their adult counterparts, the allometric relationship between total CC area and FBV has a significantly greater slope in female neonates than in adult females ($t[54] = 2.6$, $p = .012$). As can be seen by the overlap of the confidence intervals for the male neonates with the fit-line for their adult counterparts, the allometric relationship between total CC area and FBV does not differ significantly between male neonates and adult males ($t[69] = 0.6$, $p = .574$). The results of the regression analysis for the frontal lobe and the anterior portion of the CC are shown in Table 3 and Figure 5 (left). The results of the regression analysis for the posterior lobes and the posterior portion of the CC are shown in Table 4 and Figure 5 (right).

These results clearly identify the sexual dimorphism seen in the allometric relationship between CC size and brain size as being predominantly due to a difference in the relationship between the size of the anterior of the CC and the size of the frontal lobe. It should be noted that the frontal lobe in female neonates is significantly smaller than the frontal lobe in male neonates ($p < .001$).

4 | DISCUSSION

Previous research has established that larger brains have larger corpora callosa, in both men and women, and that that relationship is allometric with an exponent not significantly different from 2/3, as expected for proportional scaling of a cross-sectional area to a volume (Jäncke & Steinmetz, 1998). As pointed out by Bishop and Wahlsten (1997), the failure to take this allometric relationship into account rendered previous claims of a sexual dimorphism in the CC questionable. The same holds for subsequent studies which have failed to take this allometric relationship into account. Group comparisons based on absolute measures, ratios, or linear controls, have been determined to be potentially quite misleading (Packard & Boardman, 1988). To date then, the question of whether or not there is a sexual dimorphism in the CC remains in doubt, but the existing evidence suggests that in adults there is not.

There is, however, some evidence that there are developmental changes in this allometric relationship (Schmied et al., 2020). Schmied et al. (2020) reported that male and female infants showed divergent trajectories after six months of age, with male infants showing more rapid expansion of the CC than female infants (cf. Danielsen et al., 2020). Interestingly, Schmied et al. (2020) reported that there was no sexual dimorphism in infants at 6 months of age. Those results suggest that the sexual dimorphism may be due, at least in part, to postnatal processes such as e.g. myelination. But they do not preclude the possibility that allometric scaling may show a complex trajectory, with fluctuations throughout development. The results here suggest that this is the case, and that prenatal processes may produce still earlier sexual dimorphism in the CC. We have shown that male

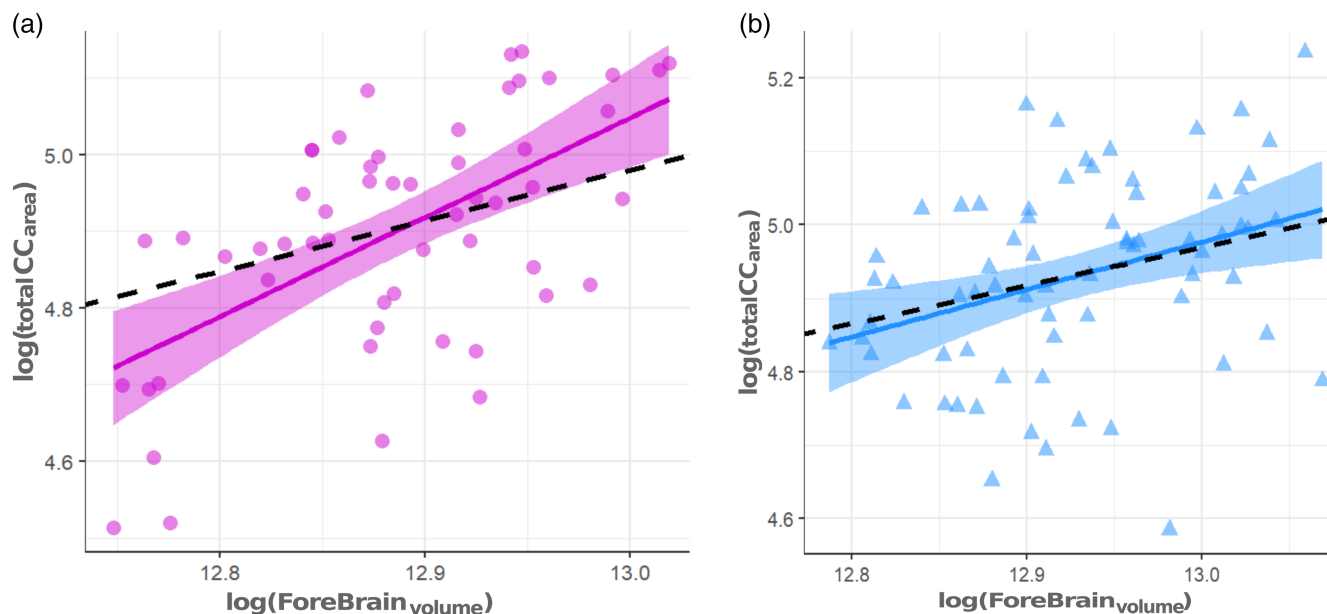


FIGURE 4 Scatter plots of the allometric relationship between $\log(\text{totalCC}_{\text{area}})$ and $\log(\text{ForeBrain}_{\text{volume}})$ in (left) female neonates in comparison to the fitline for their adult counterparts according to Jäncke and Steinmetz (1998); and in (right) male neonates in comparison to the fitline for their adult counterparts according to Jäncke and Steinmetz (1998). Female neonates are shown as magenta circles with a solid magenta regression line; the regression line for adult females is dashed. Male neonates are shown as blue triangles with a solid blue regression line; the regression line for adult males is dashed. The slope of the regression line in female neonates is 1.31; the slope of the regression line in their adult counterparts is 0.66. These slopes are significantly different ($t[54] = 2.6, p = .012$). The slope of the regression line in male neonates is 0.65; the slope of the regression line in their adult counterparts is 0.52. These slopes are not significantly different ($t[69] = 0.6, p = .574$)

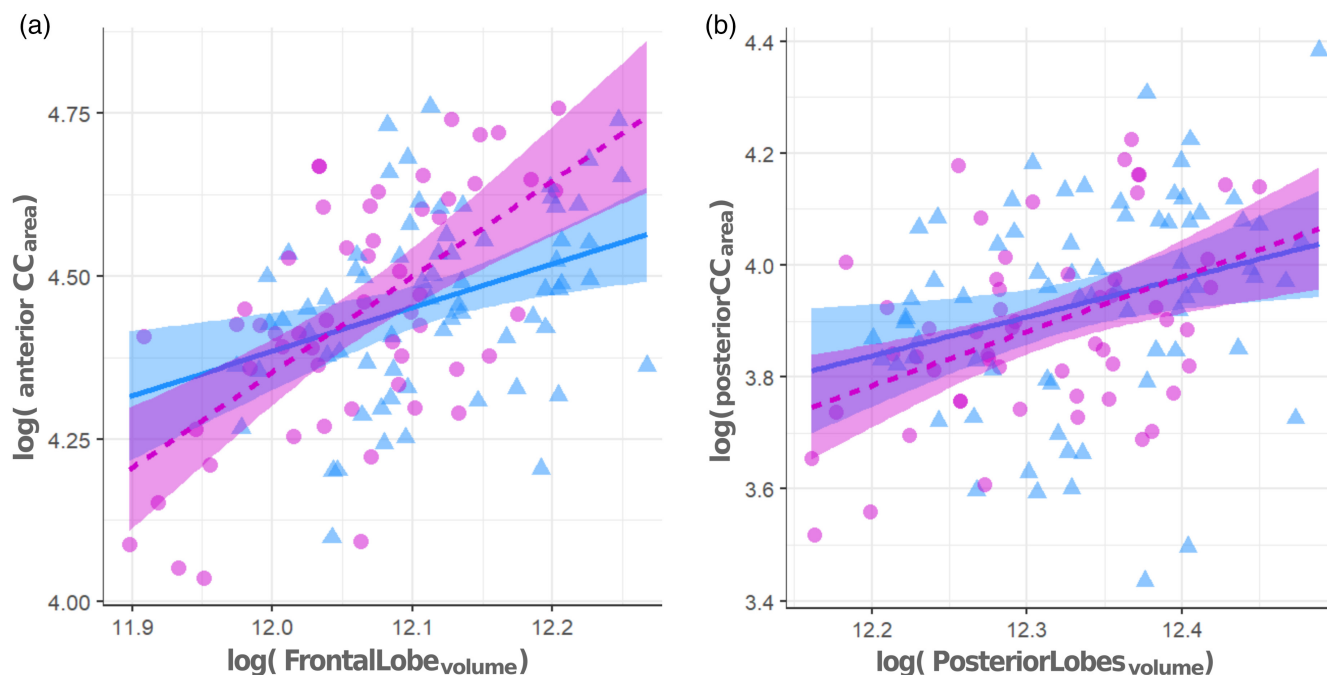


FIGURE 5 Scatter plots of the allometric relationship between $\log(\text{anteriorCC}_{\text{area}})$ and $\log(\text{FrontalLobe}_{\text{volume}})$ in male and female neonates (left), and between $\log(\text{posteriorCC}_{\text{area}})$ and $\log(\text{PosteriorLobes}_{\text{volume}})$ in male and female neonates (right). Males are shown as blue triangles; females as magenta circles. The male regression line is solid blue; the female regression line is dashed magenta. The slope of the regression line for the anterior CC in male neonates is 0.69; the slope of the regression line in female neonates is 1.45. These slopes are significantly different, that is, sexually dimorphic ($p = .018$). The slope of the regression line for the posterior CC in male neonates is 0.69; the slope of the regression line for the posterior CC in female neonates is 0.94. These slopes are not significantly different ($p = .4$).

neonates show an adult-like allometric relationship between their CC size and FBV, but female neonates show a significantly greater exponent in their allometric relationship than do either male neonates or adults of either sex. Future research must, of course, verify that there are such developmental fluctuations in the allometric scaling of the CC. Research providing charts of brain growth from infancy to maturity (Bethlehem et al., 2022; Howell et al., 2019; Rutherford et al., 2022) are an important step forward, but need to be augmented with the data that will allow assessments of the allometric relationships.

The fact that female neonates show a significantly greater exponent in this allometric relationship than do their adult counterparts is, in a sense, unsurprising. The cortex, and connectivity, in general, is known to develop through exuberance and pruning (Innocenti et al., 1977; Innocenti & Price, 2005; Low & Cheng, 2006; Luo & O'Leary, 2005; Price & Blakemore, 1985; Stiles & Jernigan, 2010). Throughout the brain, many times more neurons, glia, synapses, and connections, are produced than will ultimately survive into adulthood. In the case of connectivity, this progressive phase is largely complete by the end of the second trimester. Specifically, for the case at hand, the first midline crossings are at approximately gestational week twelve and more crossing fibers continue to be produced until about 20 weeks (Rakic & Yakovlev, 1968). The third trimester and early postnatal development mix further progressive events, in the form of myelination and increases in axon diameter, with regressive events, in the form of natural cell death and selective pruning. We conjecture that the allometric relationship between CC size and FBV observed in adults is due to the optimization achieved by this pair of developmental processes. The allometric relationship with an exponent of $2/3$ is likely only a crude approximation of the true measures of optimization: the usefulness of the connections versus their costs. The longer connections in larger brains are more metabolically expensive, and longer connections introduce greater conduction delays (Lewis et al., 2009; Ramón, 1923; Ringo et al., 1994); thus optimization should drive the observed relatively lesser connectivity in larger brains. But while the over-production of neurons, glia, synapses, and connections, is largely complete by the end of the second trimester, the elimination of the excess takes place over an extended period of time. Thus, the fact that female neonates show a significantly greater exponent in this allometric relationship than do their adult counterparts is unsurprising; more surprising is that male neonates do not show a significantly greater exponent in their allometric relationship than do their adult counterparts. So while our data suggest that there is a sexual dimorphism in the allometric relationship between CC size and brain size in neonates, it is unclear whether this points to excessive exuberance or a delay in the deployment of regressive mechanisms in females, or to a lack of exuberance or precocious deployment of regressive mechanisms in males.

It has been suggested that gonadal hormones may impact fetal brain development (Chang et al., 2018). Indeed, evidence indicates that the neurosteroid estradiol plays a supporting role in neurogenesis (Sahab-Negah et al., 2020). Estradiol interacts with neurons to facilitate cellular functions in neurons, enabling apoptosis (Molloy

et al., 2003). It is estimated that naturally occurring cell death accounts for the loss of approximately 50% of the neurons originally generated, and that this occurs shortly after the neurons are generated (Stiles & Jernigan, 2010). Thus, sex-specific hormones can impact the number of neurons that survive until birth. Estradiol also interacts with astroglia to stimulate synthesis of neuroprogesterone (Molloy et al., 2003). Progesterone significantly increases the number of oligodendrocytes in both sexes but more so in females (Swamydas et al., 2009). Conversely, dihydrotestosterone reduces the number of oligodendrocytes in both sexes but more so in females (Swamydas et al., 2009).

But gonadal hormones are not the only way that this sexual dimorphism might be achieved. Recent animal research has demonstrated differences in growth rates and metabolism between male and female embryos before there has been sexual differentiation of the gonads (Burgoyne et al., 1995; Mittwoch, 1993). And an analysis of sex differences in gene expression during the second trimester has identified thousands of differences in gene expression, both at the individual transcript level, as well as the whole gene level (O'Brien et al., 2019). Also, recent analyses of data from the second trimester in relation to single cell RNA sequencing findings suggest subtle differences in cellular composition between the male and female human brain (Fan et al., 2018; Zhong et al., 2018). Which of these differences underlies this sexual dimorphism in the allometric relationship between CC size and brain size will be a question that future research must address.

Future research must also address the questions that arise from the fact that this sexual dimorphism was found to exist in the anterior portion of the CC, and not in the posterior portion. The anterior portion of the CC interconnects the frontal cortex, which is involved in many critical cognitive functions, such as executive function, attention, memory, and language production (Carlin et al., 2000; Chayer & Freedman, 2001; Damasio & Damasio, 2000; Dimitrov et al., 1996; Miotto & Morris, 1998; Putnam et al., 2008; Rueckert & Grafman, 1996; Stuss et al., 1982). Current evidence suggests that these aspects of cognition are more lateralized in men than in women (Clements et al., 2006; Goldberg et al., 1994; Gur et al., 2012; Gur & Gur, 2017; Halpern et al., 2007; Kansaku & Kitazawa, 2001; Williams et al., 2009), suggesting a relationship between the results here and functional lateralization of these cognitive functions. But those results are in adolescents and adults; there is, though, some evidence that some of these cognitive functions are initially more bilateral (Olulade et al., 2020). The fact that the frontal lobe is significantly smaller in female neonates compared to male neonates suggests that frontal lobe connectivity, in general, develops more slowly in females; perhaps this leads to the initial bilaterality of frontal lobe functions remaining more bilateral in the mature female brain compared to males. But future research must seek to verify our speculation of a link between this sexual dimorphism in functional lateralization in older individuals and our results showing sexual dimorphism in neonates in the allometric relationship between CC size and brain size; and to explain the fact that this effect is restricted to the anterior of the CC.

It should be noted that obtaining reliable anatomical measures in neonates, such as the area of the CC or the volume of structures, is notoriously difficult. This is particularly an issue when the measures depend on image contrast, which is quite low. The measures here, though, are all based on registration between the individual neonate MRI and the neonate template, rendering the low-contrast less problematic. Further, all registrations were manually checked to ensure the validity of the measures.

It should also be noted that the division of the CC into subregions and the mapping of the cortex to those subregions originated in adult data. This potentially admits some distortion in the placement of the subregion boundaries in the neonates; but this method (a) allows the diffusion tractography results from the adults to be used to determine the anterior versus posterior measures of the CC (which cannot, as of yet, be obtained from the neonate data); and (b) in future work will allow comparisons of measures across development.

ACKNOWLEDGMENTS

This work was supported by the Academy of Finland (grant numbers 264363, 253270, 134950 to Hasse Karlsson; grant numbers 1350941 and 253346 to TP; grant number 308176 to Linnea Karlsson), the Jane and Aatos Erkko Foundation (to Hasse Karlsson), the Varsinais-Suomen Sairaanhoidopiiri State Research Grants (grant number P3006 to Jetro J Tuulari, grant number P3003 to Noora M. Scheinin, grant number P3498 to Hasse Karlsson, grant number P3654 to Linnea Karlsson, K3562 to Riitta Parkkola), the Signe and Ane Gyllenberg Foundation (to Hasse Karlsson, Noora M. Scheinin and Linnea Karlsson), the Yrjö Jahnssoonin Säätiö (grant number 6847 to Linnea Karlsson), the Alfred Kordellin Foundation (to Jetro J Tuulari), the Turku University Foundation (to Jetro J Tuulari), the Emil Aaltosen Säätiö (to Jetro J Tuulari), the Maire Taponen Foundation (to Satu J Lehtola), the Juho Vainio Foundation (to Satu J Lehtola), the Sigrid Jusélius Foundation (to Jetro J Tuulari), the NARSAD Brain and Behavior Research Foundation (grant number 1956 to Linnea Karlsson), the Foundation for Pediatric Research (to Riitta Parkkola), the Canadian Institutes of Health Research (to Vladimir S. Fonov and D. Louis Collins) and the Natural Sciences and Engineering Research Council of Canada (to D. Louis Collins). The research also benefited from computational resources provided by Compute Canada (www.computeCanada.ca) and Calcul Quebec (www.calculquebec.ca).

CONFLICT OF INTEREST

The authors declares there is no potential conflicts of interest.

DATA AVAILABILITY STATEMENT

Finnish legislation and our Ethical Board do not permit the open data sharing of the imaging data or derived measures. The analysis code can be made available upon request to the corresponding author.

ORCID

John D. Lewis  <https://orcid.org/0000-0002-0832-7396>

Henriette Acosta  <https://orcid.org/0000-0001-8580-1402>

Jetro J. Tuulari  <https://orcid.org/0000-0002-1797-8000>

Vladimir S. Fonov  <https://orcid.org/0000-0003-3402-7749>

D. Louis Collins  <https://orcid.org/0000-0002-8432-7021>

Kristian Lidauer  <https://orcid.org/0000-0003-1389-2637>

Linnea Karlsson  <https://orcid.org/0000-0002-4725-0176>

Hasse Karlsson  <https://orcid.org/0000-0002-4992-1893>

REFERENCES

- Akelaitis, A. J. (1941). Studies on the corpus callosum: II. The higher visual functions in each homonymous field following complete section of the corpus callosum. *Archives of Neurology and Psychiatry*, 45, 788–796.
- Ardesch, D. J., Scholtens, L. H., de Lange, S. C., Roumazeilles, L., Khrapitchev, A. A., Preuss, T. M., Rilling, J. K., Mars, R. B., & van den Heuvel, M. P. (2021). Scaling principles of white matter connectivity in the human and nonhuman primate brain. *Cerebral Cortex*, *bhab384*. <https://doi.org/10.1093/cercor/bhab384>
- Avants, B. B., Tustison, N., & Song, G. (2009). Advanced normalization tools (ANTs). *Insight j*, 2, 1–35.
- Bethlehem, R. A., Seidlitz, J., White, S., Vogel, J., Anderson, K., Adamson, C., Adler, S., Alexopoulos, G., Anagnostou, E., Areces-Gonzalez, A., et al. (2022). Brain charts for the human lifespan. *Nature*, 604, 525–533.
- Bishop, K. M., & Wahlsten, D. (1997). Sex differences in the human corpus callosum: Myth or reality? *Neuroscience & Biobehavioral Reviews*, 21, 581–601.
- Bruner, E., de la Cuetara, J. M., Colom, R., & Martin-Loeches, M. (2012). Gender-based differences in the shape of the human corpus callosum are associated with allometric variations. *Journal of Anatomy*, 220, 417–421.
- Burgoyne, P., Thornhill, A., Boudrean, S. K., Darling, S., Bishop, C., & Evans, E. (1995). The genetic basis of xx-xy differences present before gonadal sex differentiation in the mouse. *Philosophical transactions of the Royal Society of London. Series B: Biological Sciences*, 350, 253–261.
- Carlin, D., Bonerba, J., Phipps, M., Alexander, G., Shapiro, M., & Grafman, J. (2000). Planning impairments in frontal lobe dementia and frontal lobe lesion patients. *Neuropsychologia*, 38, 655–665.
- Chang, C. L., Chiu, N. C., Yang, Y. C., Ho, C. S., & Hung, K. L. (2018). Normal development of the corpus callosum and evolution of corpus callosum sexual dimorphism in infancy. *Journal of Ultrasound in Medicine*, 37, 869–877.
- Chayer, C., & Freedman, M. (2001). Frontal lobe functions. *Current Neurology and Neuroscience Reports*, 1, 547–552.
- Clarke, S., Kraftsik, R., van der Loos, H., & Innocenti, G. M. (1989). Forms and measures of adult and developing human corpus callosum: Is there sexual dimorphism? *Journal of Comparative Neurology*, 280, 213–230.
- Clements, A., Rimrod, S., Abel, J., Blankner, J., Mostofsky, S., Pekar, J., Denckla, M., & Cutting, L. (2006). Sex differences in cerebral laterality of language and visuospatial processing. *Brain and Language*, 98, 150–158.
- Collins, D. L., Neelin, P., Peters, T. M., & Evans, A. C. (1994). Automatic 3D intersubject registration of MR volumetric data in standardized Talairach space. *Journal of Computer Assisted Tomography*, 18, 192–205.
- Collins, D. L., Zijdenbos, A. P., Baaré, W. F., & Evans, A. C. (1999). ANIMAL+INSECT: Improved cortical structure segmentation. *Biennial International Conference on Information Processing in Medical Imaging*, Springer, 210–223.
- Damasio, A. R., & Damasio, H. (2000). Aphasia and the neural basis of language. *Principles of behavioral and cognitive neurology* (pp. 294–315). Oxford University Press.
- Danielsen, V. M., Vidal-Piñeiro, D., Mowinckel, A. M., Sederevicius, D., Fjell, A. M., Walhovd, K. B., & Westerhausen, R. (2020). Lifespan trajectories of relative corpus callosum thickness: Regional differences and cognitive relevance. *Cortex*, 130, 127–141.

- DeLacoste-Utamsing, C., & Holloway, R. L. (1982). Sexual dimorphism in the human corpus callosum. *Science*, *216*, 1431–1432.
- Dimitrov, M., Grafman, J., & Hollnagel, C. (1996). The effects of frontal lobe damage on everyday problem solving. *Cortex*, *32*, 357–366.
- Fan, X., Dong, J., Zhong, S., Wei, Y., Wu, Q., Yan, L., Yong, J., Sun, L., Wang, X., Zhao, Y., Wang, W., Yan, J., Wang, X., Qiao, J., & Tang, F. (2018). Spatial transcriptomic survey of human embryonic cerebral cortex by single-cell rna-seq analysis. *Cell Research*, *28*, 730–745.
- Fonov, V., Evans, A. C., Botteron, K., Almli, C. R., McKinstry, R. C., Collins, D. L., Group, B.D.C., et al. (2011). Unbiased average age-appropriate atlases for pediatric studies. *NeuroImage*, *54*, 313–327.
- Fonov, V. S., Evans, A. C., McKinstry, R. C., Almli, C., & Collins, D. (2009). Unbiased nonlinear average age-appropriate brain templates from birth to adulthood. *NeuroImage*, *S102*, S102.
- Goldberg, E., Harner, R., Lovell, M., Podell, K., & Riggio, S. (1994). Cognitive bias, functional cortical geometry, and the frontal lobes: Laterality, sex, and handedness. *Journal of Cognitive Neuroscience*, *6*, 276–296.
- Gur, R. C., & Gur, R. E. (2017). Complementarity of sex differences in brain and behavior: From laterality to multimodal neuroimaging. *Journal of Neuroscience Research*, *95*, 189–199.
- Gur, R. C., Richard, J., Calkins, M. E., Chiavacci, R., Hansen, J. A., Bilker, W. B., Loughhead, J., Connolly, J. J., Qiu, H., Mentch, F. D., Abou-Sleiman, P. M., Hakonarson, H., & Gur, R. E. (2012). Age group and sex differences in performance on a computerized neurocognitive battery in children age 8–21. *Neuropsychology*, *26*, 251–265.
- Halpern, D. F., Benbow, C. P., Geary, D. C., Gur, R. C., Hyde, J. S., & Gernsbacher, M. A. (2007). The science of sex differences in science and mathematics. *Psychological Science in the Public Interest*, *8*, 1–51.
- Hines, M., Chiu, L., McAdams, L. A., Bentler, P. M., & Lipcamon, J. (1992). Cognition and the corpus callosum: Verbal fluency, visuospatial ability, and language lateralization related to midsagittal surface areas of callosal subregions. *Behavioral Neuroscience*, *106*, 3–14.
- Howell, B. R., Styner, M. A., Gao, W., Yap, P. T., Wang, L., Baluyot, K., Yacoub, E., Chen, G., Potts, T., Salzwedel, A., Li, G., Gilmore, J. H., Piven, J., Smith, J. K., Shen, D., Ugarbil, K., Zhu, H., Lin, W., & Ellison, J. T. (2019). The unc/umn baby connectome project (bcnp): An overview of the study design and protocol development. *NeuroImage*, *185*, 891–905.
- Huxley, J. S., & Teissier, G. (1936). Terminology of relative growth. *Nature*, *137*, 780–781.
- Innocenti, G. M., Fiore, L., & Caminiti, R. (1977). Exuberant projection into the corpus callosum from the visual cortex of newborn cats. *Neuroscience Letters*, *4*, 237–242.
- Innocenti, G. M., & Price, D. J. (2005). Exuberance in the development of cortical networks. *Nature Reviews Neuroscience*, *6*, 955–965.
- Iwamura, Y. (2000). Bilateral receptive field neurons and callosal connections in the somatosensory cortex. *Philosophical transactions of the Royal Society of London. Series B: Biological Sciences*, *355*, 267–273.
- Jäncke, L., Liem, F., & Merillat, S. (2019). Scaling of brain compartments to brain size. *Neuroreport*, *30*, 573–579.
- Jäncke, L., Staiger, J. F., Schlaug, G., Huang, Y., & Steinmetz, H. (1997). The relationship between corpus callosum size and forebrain volume. *Cerebral cortex (New York, NY: 1991)*, *7*, 48–56.
- Jäncke, L., & Steinmetz, H. (1998). Brain size: a possible source of inter-individual variability in corpus callosum morphology. In E. Zaidel, M. Iacoboni, & A. P. Pascual-Leone (Eds.), *The role of the corpus callosum in sensory motor integration: anatomy, physiology, and behavior; individual differences and clinical applications* (pp. 1–15). Plenum Press.
- Jäncke, L., & Steinmetz, H. (2003). The parallel brain: The cognitive neuroscience of the corpus callosum. In *Brain size: A possible source of inter-individual variability in corpus callosum morphology* (pp. 51–63). MIT Press.
- Kansaku, K., & Kitazawa, S. (2001). Imaging studies on sex differences in the lateralization of language. *Neuroscience Research*, *41*, 333–337.
- Karlsson, L., Tolvanen, M., Scheinin, N. M., Uusitupa, H. M., Korja, R., Ekholm, E., Tuulari, J. J., Pajulo, M., Huottilainen, M., Paunio, T., Karlsson, H., & FinnBrain Birth Cohort Study Group. (2018). Cohort profile: The finnbrain birth cohort study (finnbrain). *International Journal of Epidemiology*, *47*, 15–16j.
- Leonard, C. M., Towler, S., Welcome, S., Halderman, L. K., Otto, R., Eckert, M. A., & Chiarello, C. (2008). Size matters: Cerebral volume influences sex differences in neuroanatomy. *Cerebral Cortex*, *18*, 2920–2931.
- Lewis, J. D., Theilmann, R. J., Fonov, V., Bellec, P., Lincoln, A., Evans, A. C., & Townsend, J. (2013). Callosal fiber length and interhemispheric connectivity in adults with autism: Brain overgrowth and underconnectivity. *Human Brain Mapping*, *34*, 1685–1695.
- Lewis, J. D., Theilmann, R. J., Sereno, M. I., & Townsend, J. (2009). The relation between connection length and degree of connectivity in young adults: A dti analysis. *Cerebral Cortex*, *19*, 554–562.
- Low, L. K., & Cheng, H. J. (2006). Axon pruning: An essential step underlying the developmental plasticity of neuronal connections. *Philosophical Transactions of the Royal Society B: Biological Sciences*, *361*, 1531–1544.
- Luders, E., Toga, A. W., & Thompson, P. M. (2014). Why size matters: Differences in brain volume account for apparent sex differences in callosal anatomy: The sexual dimorphism of the corpus callosum. *NeuroImage*, *84*, 820–824.
- Luo, L., & O'Leary, D. D. (2005). Axon retraction and degeneration in development and disease. *Annual Review of Neuroscience*, *28*, 127–156.
- Miotto, E. C., & Morris, R. G. (1998). Virtual planning in patients with frontal lobe lesions. *Cortex*, *34*, 639–657.
- Mitchell, D. E., & Blakemore, C. (1970). Binocular depth perception and the corpus callosum. *Vision Research*, *10*, 49–54.
- Mittwoch, U. (1993). Blastocysts prepare for the race to be male. *Human Reproduction*, *8*, 1550–1555.
- Molloy, E. J., O'Neill, A. J., Grantham, J. J., Sheridan-Pereira, M., Fitzpatrick, J. M., Webb, D. W., & Watson, R. W. G. (2003). Sex-specific alterations in neutrophil apoptosis: The role of estradiol and progesterone. *Blood*, *102*, 2653–2659.
- O'Brien, H. E., Hannon, E., Jeffries, A. R., Davies, W., Hill, M. J., Anney, R. J., O'Donovan, M. C., Mill, J., & Bray, N. J. (2019). Sex differences in gene expression in the human fetal brain. *bioRxiv*, 483636.
- Olulade, O. A., Seydell-Greenwald, A., Chambers, C. E., Turkeltaub, P. E., Dromerick, A. W., Berl, M. M., Gaillard, W. D., & Newport, E. L. (2020). The neural basis of language development: Changes in lateralization over age. *Proceedings of the National Academy of Sciences*, *117*, 23477–23483.
- Packard, G. C., & Boardman, T. J. (1988). The misuse of ratios, indices, and percentages in ecophysiological research. *Physiological Zoology*, *61*, 1–9.
- Price, D. J., & Blakemore, C. (1985). Regressive events in the postnatal development of association projections in the visual cortex. *Nature*, *316*, 721–724.
- Putnam, M. C., Wig, G. S., Grafton, S. T., Kelley, W. M., & Gazzaniga, M. S. (2008). Structural organization of the corpus callosum predicts the extent and impact of cortical activity in the nondominant hemisphere. *Journal of Neuroscience*, *28*, 2912–2918.
- Rakic, P., & Yakovlev, P. I. (1968). Development of the corpus callosum and cavum septi in man. *Journal of Comparative Neurology*, *132*, 45–72.
- Ramón, S., 1923. Recuerdos de mi vida: Obra ilustrada con numerosos fotograbados. 1. P. Mi infancia y juventud.(2. P. Historia de mi labor científica.). Imprenta de Juan Pueyo.
- Ringo, J. L., Doty, R. W., Demeter, S., & Simard, P. Y. (1994). Time is of the essence: A conjecture that hemispheric specialization arises from interhemispheric conduction delay. *Cerebral Cortex*, *4*, 331–343.
- Rueckert, L., & Grafman, J. (1996). Sustained attention deficits in patients with right frontal lesions. *Neuropsychologia*, *34*, 953–963.

- Rutherford, S., Frazza, C., Dinga, R., Kia, S. M., Wolfers, T., Zabihi, M., Berthet, P., Worker, A., Verdi, S., Andrews, D., Han, L. K. M., Bayer, J. M. M., Dazzan, P., McGuire, P., Mocking, R. T., Schene, A., Sripada, C., Tso, I. F., Duval, E. R., ... Marquand, A. F. (2022). Charting brain growth and aging at high spatial precision. *eLife*, *11*, e72904.
- Sahab-Negah, S., Hajali, V., Moradi, H. R., & Gorji, A. (2020). The impact of estradiol on neurogenesis and cognitive functions in alzheimer's disease. *Cellular and Molecular Neurobiology*, *40*, 283–299.
- Schmidt-Nielsen, K., & Knut, S. N. (1984). *Scaling: Why is animal size so important?* Cambridge University Press.
- Schmied, A., Soda, T., Gerig, G., Styner, M., Swanson, M. R., Elison, J. T., Shen, M. D., McKinstry, R. C., Pruett, J. R., Jr., Botteron, K. N., et al. (2020). Sex differences associated with corpus callosum development in human infants: A longitudinal multimodal imaging study. *NeuroImage*, *215*, 116821.
- Selnes, O. A. (1974). The corpus callosum: Some anatomical and functional considerations with special reference to language. *Brain and Language*, *1*, 111–139.
- Sled, J. G., Zijdenbos, A. P., & Evans, A. C. (1998). A nonparametric method for automatic correction of intensity nonuniformity in MRI data. *Medical Imaging, IEEE Transactions on*, *17*, 87–97.
- Smith, R. (2005). Relative size versus controlling for size: Interpretation of ratios in research on sexual dimorphism in the human corpus callosum. *Current Anthropology*, *46*, 249–273.
- Stiles, J., & Jernigan, T. L. (2010). The basics of brain development. *Neuropsychology Review*, *20*, 327–348.
- Stuss, D., Kaplan, E., Benson, D., Weir, W., Steven, C., & Sarazin, F. (1982). Evidence for involvement of orbitofrontal cortex in memory functions: An interference effect. *Journal of Comparative and Physiological Psychology*, *96*, 913–925.
- Swamydas, M., Bessert, D., & Skoff, R. (2009). Sexual dimorphism of oligodendrocytes is mediated by differential regulation of signaling pathways. *Journal of Neuroscience Research*, *87*, 3306–3319.
- Ward, J. H. J. (1963). Hierarchical grouping to optimize an objective function. *Journal of the American Statistical Association*, *58*, 236–244.
- Westheimer, G., & Mitchell, D. E. (1969). The sensory stimulus for disjunctive eye movements. *Vision Research*, *9*, 749–755.
- Williams, L. M., Mathersul, D., Palmer, D. M., Gur, R. C., Gur, R. E., & Gordon, E. (2009). Explicit identification and implicit recognition of facial emotions: I. age effects in males and females across 10 decades. *Journal of Clinical and Experimental Neuropsychology*, *31*, 257–277.
- Witelson, S. F. (1989). Hand and sex differences in the isthmus and genu of the human corpus callosum: A postmortem morphological study. *Brain*, *112*, 799–835.
- Zhong, S., Zhang, S., Fan, X., Wu, Q., Yan, L., Dong, J., Zhang, H., Li, L., Sun, L., Pan, N., Xu, X., Tang, F., Zhang, J., Qiao, J., & Wang, X. (2018). A single-cell rna-seq survey of the developmental landscape of the human prefrontal cortex. *Nature*, *555*, 524–528.

How to cite this article: Lewis, J. D., Acosta, H., Tuulari, J. J., Fonov, V. S., Collins, D. L., Scheinin, N. M., Lehtola, S. J., Rosberg, A., Lidauer, K., Ukharova, E., Saunavaara, J., Parkkola, R., Lähdesmäki, T., Karlsson, L., & Karlsson, H. (2022). Allometry in the corpus callosum in neonates: Sexual dimorphism. *Human Brain Mapping*, *43*(15), 4609–4619. <https://doi.org/10.1002/hbm.25977>